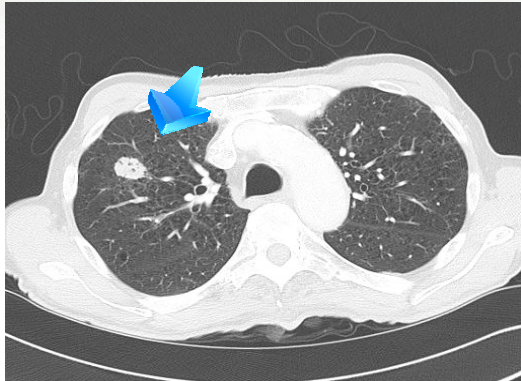
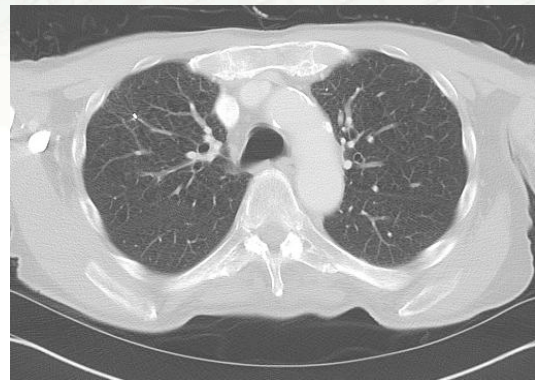


## CASE STUDY Non-small Cell Lung Cancer



Pre-treatment CT shows RUL mass



Post-treatment CT

### Patient History

An 81-year-old male smoker presented in the ER with chest pain. The CT scan of the chest on 11-1-09 revealed a 2.1 cm right upper lobe lung mass. A follow-up PET scan on 11-13-09 showed the lesion to be hypermetabolic with an SUV of 9. His pulmonologist performed a biopsy with the superDimension inReach<sup>®</sup> electromagnetic navigation bronchoscopy system. The location of this tumor would have been more difficult to reach with other biopsy techniques and would have exposed the patient to a much higher chance of complications; i.e., a pneumothorax. The pulmonary function test showed his FEV1 to be 72% of predicted value. The biopsy revealed poorly differentiated non-small cell carcinoma (T1AN0M0). The patient was deemed an inoperable candidate secondary to his age and medical comorbidities. Fiducial markers were placed during the superDimension inReach bronchoscopy without any complications.

### CyberKnife<sup>®</sup> Advantage

CyberKnife radiosurgery was chosen by the patient after he was presented with other radiation options. Recent radiosurgical studies demonstrate a projected 90% local control rate for the primary tumor and overall disease survival rate of approximately 70% with a low side effect profile. This cure rate is significantly higher than conventional radiation therapy that involves more treatments over several weeks. Stereotactic radiosurgery with CyberKnife involves constant tracking of the lesion during a patient's normal respiration using Synchrony System technology, so there is no need for breath holding - an important benefit to the patient who may have COPD or another lung condition that makes breath holding difficult. In contrast, during conventional lung radiation therapy, breath holding techniques are often used, resulting in larger areas of healthy lung being treated.

### Treatment

On 11-25-09, the patient was brought into the CyberKnife Center and was fitted for a Synchrony vest and a Vac-Lock body immobilization device before he underwent a CT with PET fusion. The patient received a dose of 60 Gy prescribed to the 81% isodose line in three (3) fractions. He tolerated the treatment well and resumed normal activities.

### Outcome & Follow-Up

The 4-month follow-up CT of the chest showed some fibrosis at the site of the previous RUL mass, but otherwise no evidence of disease.

### CyberKnife Team:

Brent Mahoney, MD, PhD, Radiation Oncologist

Gary Guidry, MD, Pulmonologist

Meyer Heiman, MS, Medical Physicist

**If you would like your patient case reviewed at our weekly case conference, call 337-289-8070.**

 **CyberKnife Center**  
Louisiana  
[www.CyberKnifeLa.com](http://www.CyberKnifeLa.com)